

Surgical Outcome of Endoscopic Third Ventriculostomy in the Treatment of Obstructive Hydrocephalus

Zia-Ur-Rehman*, Bashir Ullah, Muhammad Aamir

Lady Reading Hospital MTI Peshawar, Pakistan

*Corresponding author's email address: drziaktk@gmail.com

(Received, 24th November 2024, Accepted 22nd May 2025, Published 31st May 2025)

Abstract: Hydrocephalus is the dilation of the cerebral ventricles, which can occur due to obstructed circulation of cerebrospinal fluid (CSF). In cases of communicative hydrocephalus, the blockage of cerebrospinal fluid circulation occurs due to a decrease in the absorption of CSF by the arachnoid granulations. On the other hand, non-communicating hydrocephalus is due to a blockage that occurs closer to the granulations, such as a narrowing of the aqueduct of Sylvius. **Objective:** To determine the surgical outcome in terms of success of ETV in obstructive hydrocephalus. **Methods:** Sixty-two patients presenting with obstructive hydrocephalus were treated with the ETV procedure over the period of one year. The success rate of ETV was determined. **Results:** Thirty-eight (61.3%) male and 24 (38.7%) female patients were treated for obstructive hydrocephalus. The mean age was 11.68±9.94 years. ETV was successful in 48 (77.4%) patients. **Conclusion:** ETV is an effective and efficient surgical treatment for obstructive hydrocephalus with a success rate of 77.4%.

Keywords: Obstructive hydrocephalus, Endoscopic Third Ventriculostomy, Efficacy, Adults, Pediatrics

[How to Cite: Rehman ZU, Ullah B, Aamir M. Surgical outcome of endoscopic third ventriculostomy in the treatment of obstructive hydrocephalus. *Biol. Clin. Sci. Res. J.*, 2025; 6(5): 162-164. doi: <https://doi.org/10.54112/bcsrj.v6i5.1782>

Introduction

Hydrocephalus is the dilation of the cerebral ventricles, which can occur due to obstructed circulation of cerebrospinal fluid (CSF). In cases of communicative hydrocephalus, the blockage of cerebrospinal fluid circulation occurs due to a decrease in the absorption of CSF by the arachnoid granulations (1, 2). On the other hand, non-communicating hydrocephalus is due to a blockage that occurs closer to the granulations, such as a narrowing of the aqueduct of Sylvius (3, 4). ETV represents a less invasive approach used to treat obstructive hydrocephalus (5). The ETV facilitates the flow of CSF from the third ventricle to the subarachnoid areas, circumventing any blockage in the aqueduct and fourth ventricle. As a result, ETV reduces the size of both lateral and third ventricles, leading to a decrease in intracranial pressure (ICP). The third ventricle must be adequately expanded to permit the endoscope to move within it without causing harm to the ventricle's lateral walls. For the therapy of hydrocephalus, available methods include ventriculoperitoneal shunts (VPS) and ETV (6-8). One benefit of ETV is the reduced likelihood of enduring long-term problems, primarily related to infections or malfunctioning of the device resulting from the presence of a foreign item. ETV has been widely acknowledged as the preferred method for treating OHC in both children and adults. The implementation of ETV raises a contentious question regarding the potential ineffectiveness of the treatment in children below a certain age threshold (9, 10). There has been a renewed interest in utilizing ETV for a wider range of medical conditions. This is because to the advancements in endoscope technology, such as fiber-optics and sophisticated light sources, which provide high-resolution imaging of the ventricular architecture and enable precise fenestration of the floor of the third ventricle in a safe manner (11, 12). Endoscopic resection is a viable option for the removal of colloid cysts. ETV may be considered as a treatment option in cases where shunting fails to produce desired results or when there are issues related to VPS that are caused by infection (13, 14). Traditionally, communicating hydrocephalus has been considered a contraindication to ETV. There is empirical data suggesting that Endoscopic Third Ventriculostomy (ETV) may yield positive outcomes in certain patients diagnosed with NPH (15). Multiple studies have attempted to clarify the surgical results of ETV, to

determine its effectiveness as a feasible therapy choice for hydrocephalus. Research has shown positive outcomes, with a substantial number of patients achieving alleviation from symptoms and a decreased dependence on shunt devices. Due to the paucity of literature on this subject on local level, the goal of this study is to determine the surgical outcome of ETV in patients presented with obstructive hydrocephalus. The findings of this study will be helpful in considering the evolving landscape of neurosurgery and its potential to reshape the standard of care for hydrocephalus.

Methodology

A prospective case series was conducted at department of neurosurgery ABC hospital on 62 patients with obstructive hydrocephalus who went through endoscopic third ventriculostomy. The procedure was performed on these patients over a period of one year from July 2022 to July 2023. Patients were less than fifty years of age of either gender. Written consent was taken from the patients who were adults while the parents of the minors and infant patients gave in their consent. We excluded pregnant patients, patients having age less than one year and having previous history of ETV procedure.

The patients were placed in a supine posture with a slight inclination of the head. A surgical incision was made at Kocher's point to generate a burr hole. By employing a protected inflexible endoscope with a 0-degree inclination, entry was achieved into the lateral ventricle. The third ventricle was accessed via Monroe's foramen, with careful consideration to prevent any damage to the fornix or vascular systems in this area. After identifying the landmarks, the blunt end of a monopolar lead, which did not have any energy applied to it, pierced the floor of the third ventricle. Afterwards, the Fogarty catheter was inflated in order to enlarge the stoma. Prior to the usual closure, the basilar artery was visualized and the pulsations of CSF fluid were observed at the stoma site. Follow-up period was of 6 months, during which all patients attended scheduled postoperative appointments. A postoperative CT scan of the brain was performed. The occurrence of ETV failure was defined as the need for a VP shunt or the requirement for a repeat ETV procedure at any time



throughout the follow-up period. All the data was recorded digitally in excel sheets and manually on a proforma.

The sample size was estimated using openepi, acquiring previous frequency of successful ETV in 80% patients¹⁶, margin of error 10% and confidence interval 95%.

All the data was analyzed using SPSS. Appropriate tests were applied for association between the outcome with various parameters to counter the bias in the study. P value was kept at < 0.05 as significant.

Results

Sixty-two patients were recruited for the study. Patients’ mean age was 11.68±9.94 years. Thirtytwo (51.6%) patients had age 1 to 10 years, twenty six (41.9%) had age 11 to 16 years while four (6.5%) patients were above sixteen years of age. Gender wise males were 38 (61.3%) while females were 24 (38.7%). Table 1 presents the causes of obstructive hydrocephalus, leading cause identified in our study was posterior fossa tumors 28 (45.2%) followed by aqueductal stenosis 18 (29%). The ETV was successful in 48 (77.4%) patients. Table 2 presents the list of post-procedure complications in our study, inadequate ventriculostomy was 5 (8.1%), bleeding was seen in 3 (4.8%) patients, two (3.2%) patients had

CSF leak. The outcome was successful in 27 (56.2%) patients having age 1 to 10 years followed by 11 to 16 years 19 (39.6%) and in patients > 16 years the outcome was successful in 2 (4.2%) patients, no association was found between outcome and age. Similarly we did not find any association of outcome with gender (Table 4).

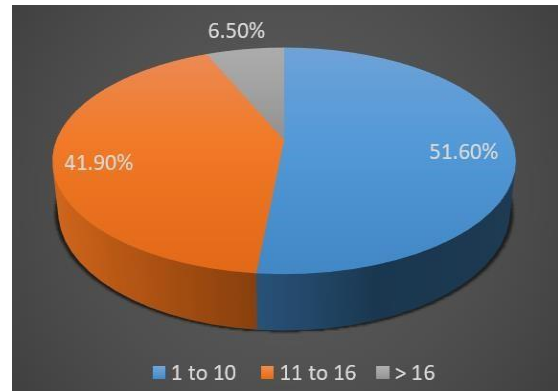


Figure:1. Distribution of age groups

Table-1: Causes of obstructive hydrocephalus

Causes of Obstructive Hydrocephalus	Frequency	Percent (%)
Posterior fossa tumors	28	45.2%
Aqueductal stenosis	18	29.0%
Tectal tumors	9	14.5%
CP angle tumors	7	11.3%
Total	62	100.0%

Table-2: Post-procedure complications

Post-procedure Complications	Frequency	Percent (%)
Inadequate ventriculostomy	5	8.1%
Bleeding	3	4.8%
CSF leak	2	3.2%
Seizures	1	1.6%
Meningitis	1	1.6%
No complication	50	80.6%
Total	62	100.0%

Table-3: Association of outcome with age

Outcome of ETV	1 to 10 years	11 to 16 years	> 16 years	Total	P value
Successful	27 (56.2%)	19 (39.6%)	2 (4.2%)	48	0.23
Not successful	5 (35.7%)	7 (50.0%)	2 (14.3%)	14	
Total	32 (51.6%)	26 (41.9%)	4 (6.5%)	62	100.0%

Table-4: Association of outcome with gender

Outcome of ETV	Male	Female	Total	P value
Successful	30 (62.5%)	18 (37.5%)	48	0.71
Not successful	8 (57.1%)	6 (42.9%)	14	
Total	38 (61.3%)	24 (38.7%)	62	100.0%

Discussion

ETV is used to treat persons with non-communicating hydrocephalus caused by blockage after the third ventricle. The goal is to redirect the abnormal flow of CSF and lower the pressure inside the skull (intracranial pressure, or ICP). Cases of congenital aqueductal stenosis are rare in our neurosurgical practice. Obstruction is typically identified by examining triventricular hydrocephalus imaging and cine-MRI scans that show the flow void phenomena. Our first concern is often the treatment of patients who have tumors that obstruct the normal flow of cerebrospinal fluid. When tumors cannot be surgically removed, ETV is used as the main treatment (17). ETV is very notable for its little invasiveness, safety, and

significant effectiveness, especially in situations of non-communicating hydrocephalus. Our study demonstrates that ETV achieves a success rate of 77.4% in the short to medium term, which is consistent with the findings of previous research conducted on specific patients with obstructive hydrocephalus (16, 17). The effectiveness of ETV in decreasing illness and overall healthcare expenses, especially in economically disadvantaged countries facing difficulties associated to shunts, is apparent. ETV is the preferred treatment for obstructive hydrocephalus, as determined by the ETV success score. In our analysis, we found that posterior fossa tumors and aqueductal stenosis were the most common causes, which aligns with the prevailing suggestions in the literature. The success rates of ETV vary depending on the cause of

hydrocephalus and the age of the patient, ranging from 40% to 90%. ETV success is influenced by clinical, radiological, and technical aspects, as well as changes in ventricular Structure (18, 19). Our study found no notable association between age groups and the successful outcome, however our study demonstrated that the percentage of success rate was higher for patients in the age bracket of 1 to 10 years and 11 to 16 years. Similarly our findings could not find an association between gender and successful outcome but we observed higher percentage of successful outcome in the male gender, a study reported similar findings, they reported higher success rate of ETV in patients having age between 1 to 10 years, they also reported higher percentage of successful ETV in their male subjects as compared to the female subjects (16). ETV is connected with complications such as CSF leak, neurovascular injury, endocrine disorders, and brain structural destruction. The most prevalent complications observed in our series were inadequate ventriculostomy, hemorrhage, and CSF leak. However, the frequency of these complications was not significant enough to establish clear conclusions.

Conclusion

From our study we conclude that ETV is an effective and efficient surgical treatment for obstructive hydrocephalus with a success rate of 77.4%. We suggest that further studies need to be conducted with VP shunt being the second treatment group and the follow up should be for a longer period of time.

Declarations

Data Availability statement

All data generated or analysed during the study are included in the manuscript.

Ethics approval and consent to participate

Approved by the department concerned. (IRBEC-MM-22)

Consent for publication

Approved

Funding

Not applicable

Conflict of interest

The authors declared the absence of a conflict of interest.

Author Contribution

ZUR (Assistant Professor)

Conception of Study, Development of Research Methodology Design, Manuscript drafting, Study Design,

BU (Postgraduate Resident)

Review of Literature, Data entry, Data analysis, and drafting article.

MA (Postgraduate Resident)

Study Design, manuscript review, critical input.

All authors reviewed the results and approved the final version of the manuscript. They are also accountable for the integrity of the study.

References

1. Leinonen V, Vanninen R, Rauramaa T. Cerebrospinal fluid circulation and hydrocephalus. *Handb Clin Neurol.* 2018;145:39-50.
2. Lolanssen SD, Rostgaard N, Oernbo EK, Juhler M, Simonsen AH, MacAulay N. Inflammatory markers in cerebrospinal fluid from patients with hydrocephalus: a systematic literature review. *Dis Markers.* 2021.
3. Abraham AP, Moorthy RK, Jeyaseelan L, Rajshekhar V. Postoperative intraventricular blood: a new modifiable risk factor for early postoperative symptomatic hydrocephalus in children with posterior fossa tumors. *Childs Nerv Syst.* 2019;35:1137-46.

4. Helmbold LJ, Kammler G, Regelsberger J, Fritzsche FS, Emami P, Schüller U, et al. Predictive factors associated with ventriculoperitoneal shunting after posterior fossa tumor surgery in children. *Childs Nerv Syst.* 2019;35:779-88.
5. Lu L, Chen H, Weng S, Xu Y. Endoscopic third ventriculostomy versus ventriculoperitoneal shunt in patients with obstructive hydrocephalus: meta-analysis of randomized controlled trials. *World Neurosurg.* 2019;129:334-40.
6. Usami K, Ishisaka E, Ogiwara H. Endoscopic third ventriculostomy and cerebrospinal fluid shunting for pure communicating hydrocephalus in children. *Childs Nerv Syst.* 2021;37(9):2813-9.
7. Al-Hakim S, Schaumann A, Tietze A, Schulz M, Thomale UW. Endoscopic third ventriculostomy in children with third ventricular pressure gradient and open ventricular outlets on MRI. *Childs Nerv Syst.* 2019;35:2319-26.
8. di Russo P, Fava A, Vandembulcke A, Miyakoshi A, Kohno M, Evins AI, et al. Characteristics and management of hydrocephalus associated with vestibular schwannomas: a systematic review. *Neurosurg Rev.* 2021;44(57):687-98.
9. Rieken S, Gaiser T, Mohr A, Welzel T, Witt O, Kulozik AE, et al. Outcome and prognostic factors of desmoplastic medulloblastoma treated within a multidisciplinary treatment concept. *BMC Cancer.* 2010;10(1):1-0.
10. Hafez RF. Stereotaxic gamma knife surgery in treatment of critically located pilocytic astrocytoma: preliminary result. *World J Surg Onc.* 2007;5(1):1-6.
11. Li D, Ravindra VM, Lam SK. Rigid versus flexible neuroendoscopy: a systematic review and meta-analysis of endoscopic third ventriculostomy for the management of pediatric hydrocephalus. *J Neurosurg.* 2021;28(4):439-49.
12. Texakalidis P, Tora MS, Wetzel JS, Chern JJ. Endoscopic third ventriculostomy versus shunt for pediatric hydrocephalus: A systematic literature review and metaanalysis. *Nervous System.* 2019;35:1283-93.
13. Unal TC, Sencer A, Dolas I, Gulsever CI, Sahin D, Dolen D, et al. Full-endoscopic removal of third ventricular colloid cysts: technique, results, and limitations. *Front Surg.* 2023;10:1174144.
14. Carretta A, Zoli M, Martinoni M, Rustici A, Conti A, Mazzatenta D, et al. Isolated entrapment of the lateral ventricle after neuroendoscopic resection of colloid cysts: single-center experience and management. *Clin Neurol Neurosurg.* 2023;232:107890.
15. Culley DJ, Berger MS, Shaw D, Geyer R. An analysis of factors determining the need for ventriculoperitoneal shunts after posterior fossa tumor surgery in children. *Neurosurgery.* 1994;34(3):402-8.
16. Farooq Azam, et al, Surgical Outcome of Endoscopic Third Ventriculostomy in Patients Having High ETV Success Score. *Pak. J. of Neurol. Surg.* 2022;26 (3): 515-520.
17. Khanzada K, Rehman Zu. Endoscopic Third Ventriculostomy: Outcome Analysis In 170 Procedures. *Khyber Med Univ J* 2014; 6(1): 25-30.
18. Morgan E, Bankole OB, Mofikoya BO, Kanu OO, Ojo OA, Jeje EA, et al. Endoscopic third ventriculostomy success score in predicting short-term outcome in 68 children with hydrocephalus in a resource-limited tertiary centre in subSaharan Africa. *Egypt J Neurosurg.* 2019; 34(1): 31.
19. El Damaty A, Marx S, Cohrs G, Vollmer M, Eltanahy A, El Refaee E, et al. ETV in infancy and childhood below 2 years of age for treatment of hydrocephalus. *Child's Nerv Syst.* 2020; 36(11): 2725-31.



Open Access This article is licensed under a Creative Commons Attribution 4.0 International License, <http://creativecommons.org/licenses/by/4.0/>. © The Author(s) 2025